



The Egyptian Society of Chest Diseases and Tuberculosis
Egyptian Journal of Chest Diseases and Tuberculosis

www.elsevier.com/locate/ejcdt
www.sciencedirect.com



ORIGINAL ARTICLE

Value of chest ultrasound in diagnosis of community acquired pneumonia



Khaled Fawzy Alkhayat *, Mohamad Hasan Alam-Eldeen

Sohag University Hospital, Egypt

Received 13 May 2014; accepted 2 June 2014

Available online 5 July 2014

KEYWORDS

Pneumonia;
Ultrasound;
X-ray

Abstract Detection of a technique used for diagnosis of Community Acquired Pneumonia by chest ultrasound compared to chest radiograph.

Study: Sixty two patients presented with clinically diagnosed pneumonia (acute presentation of fever, cough, purulent expectoration and typical auscultation as rales and bronchial breath sound), patients with chronic chest and cardiac diseases are excluded from the study. Chest ultrasound and chest X-ray were done for all patients.

Results: Chest ultrasound showed a significant diagnostic value of consolidation, as it showed signs of consolidation in 46 patients (74.2%) (P value 0.01), while Chest X-ray showed signs of consolidation in 32 patients (51.6%) (P value more than 0.05).

Conclusion: Performance of chest ultrasound for the detection of pneumonia is excellent and superior to chest X-ray considering rapid access to bedside ultrasound and the excellent performance of this simple test.

Clinical importance: This study supports the routine use of chest ultrasound for the detection of community acquired pneumonia especially in cases in which chest X-ray is contraindicated or inaccessible.

© 2014 The Egyptian Society of Chest Diseases and Tuberculosis. Production and hosting by Elsevier B.V. Open access under [CC BY-NC-ND license](https://creativecommons.org/licenses/by-nc-nd/4.0/).

Introduction

Community acquired pneumonia (CAP) is the most common disease recorded worldwide. Despite that pneumonia can be simply diagnosed by physical examination, history taking, and specific auscultatory findings, diagnosis has recently become highly dependent on imaging. In an appropriate clinical setting, diagnosis of pneumonia is established in the case of

a new infiltrate on a chest radiograph [7]. However, chest radiography is of relatively low accuracy [1]. The accuracy of chest radiography (CXR), which remains the daily reference for lung imaging and a cornerstone for the diagnosis of pneumonia according to the American Thoracic Society criteria, is 65% when compared with CT scan [17]. Additionally, common chest radiography is associated with considerable practical delays related to processing [1]. Because of the methodological limitation of a chest radiograph, CT imaging is regarded as the gold standard allowing for the diagnosis of pneumonia earlier and with a higher sensitivity and specificity [7]. However, CT scan may not always be available and is charged with a high radiation dose and high cost that precludes its use in the rou-

* Corresponding author. Tel.: +20 1003206949.

E-mail address: alkhaiat2020@yahoo.com (K.F. Alkhayat).

Peer review under responsibility of The Egyptian Society of Chest Diseases and Tuberculosis.

tine diagnostic process of patients with suspected pneumonia [2,4]. During the last 20 years, ultrasound has been shown to be highly effective in evaluating a range of pathologic pulmonary conditions [13]. One of the most widely practiced applications is the evaluation of pneumonia with ultrasound. Point-of-care ultrasound imaging, performed at the patient's bedside, decreases the delays of chest radiography in the diagnosis of pneumonia [1,5].

The objective of this study was to determine the accuracy of chest US in diagnosing CAP compared with chest radiography.

Patients and methods

The present study was carried out on 62 patients (28 males and 34 females), their age ranged from 25 to 80 years with mean age of 57.74 years, during the period from february 2013 to february 2014.

The following were done for all patients:

- (A) Careful history taking including cough, purulent expectoration, dyspnea, hemoptysis and fever $>38.0^{\circ}\text{C}$. Patient's history of co morbidity and risk factors was documented.
- (B) Clinical examination including:
 - Vital signs: heart rate, systemic blood pressure, temperature and respiratory rate.
 - Systematic examination: to exclude other coexisting diseases.
 - Chest examination: auscultation as rales and bronchial breath sound.
- (C) Chest X-ray PA and lateral views.

All patients underwent PA and lateral chest radiography on day 0 and if possible between days 7 and 15.

- (D) Chest ultrasound.

Chest US was performed within 24 h after the chest radiograph. Sonography was assessed for the location, shape, size and echogenicity of consolidation as well as necrotic areas, positive air bronchogram, fluid bronchogram and pleural effusion if present.

Chest ultrasound technique

Chest US was done by US unit (Toshiba-Xario) using a 3.5–5-MHz convex probe which allows visualization and quick survey of the pleura and lungs. A high-resolution 7.5–10-MHz linear probe was used to provide detailed depiction of any pleural or peripheral lung abnormality. In the adult patient, the field depth is typically set at 16 to 18 cm.

Each hemithorax was divided into five areas: two anterior, two lateral, one posterior, for a total of 10 areas bilaterally. The anterior chest wall was marked off from the parasternal line to the anterior axillary line. This zone was split into an upper region (from the collar bone to the second–third intercostal space) and a lower region (from the third intercostal space to the diaphragm). The lateral area (anterior to posterior axillary line) was split into upper and lower halves. Finally, the

posterior area was identified from the posterior axillary line to the paravertebral line [5].

The ultrasound transducer is moved until a rib interspace is located. The probe is then panned horizontally and vertically to the extent possible to allow the broadest sweep through the area being imaged [1]. Raising the arm above the patient's head increases the rib space distance and facilitates scanning. Before performing the US examination, the patient's chest radiograph was reviewed to localize the area of interest. Scanning was performed during quiet respiration, to allow for assessment of normal lung movement, and in suspended respiration, when a lesion can be examined in detail. The echogenicity of a lesion was compared with that of the liver and characterized as hypoechoic, isoechoic, or hyperechoic [9].

US pattern in consolidated lung

The key to ultrasound visualization of pneumonia in the lungs is relative loss of aeration of a portion of the lung and a concomitant increase in the fluid content, which is seen in lung consolidation. Once this consolidation reaches the pleura, it can be seen with ultrasound. Although some very early pneumonias are so localized as to not about the lung pleura, most make contact at some point and can thus be imaged with ultrasound [12]. In general, the size of the pneumonia appears smaller at US than on radiographs. This is because the periphery of the pneumonia is more air-filled, which results in more artifacts, thus limiting complete visualization of the extent of consolidation [6,9].

The consolidated lung is similar in echogenicity to the liver and spleen. As the disease progresses, the echogenicity increases and becomes more heterogeneous [9]. Within the consolidation, multiple bright dot-like and branching linear structures are found which represent air in the bronchi and scattered residual air in alveoli. This appearance is termed as *sonographic air bronchogram* [8]. Consolidations may contain dynamic air bronchograms (branching echogenic structures showing centrifugal movement with breathing) [11]. If the bronchial tree is filled with fluid rather than air, a branching pattern of anechoic or hypoechoic tubular structures is seen, an appearance termed as *sonographic fluid or mucus bronchogram*. When pneumonia is complicated by lung abscess, it is identified at US as a hypoechoic lesion with a well-defined or irregular wall and anechoic center sometimes with internal ech-

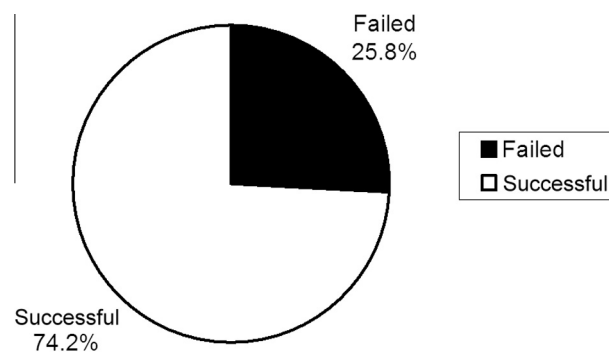


Figure 1 Outcome of chest ultrasound in the studied group.

Table 1 Demographic data of the studied patients.

Age group	Sex				Total
	Female		Male		
	No.	%	No.	%	
20–<30	2	5.9	0	0.0	2
30–<40	2	5.9	0	0.0	2
40–<50	4	11.8	0	0.0	4
50–<60	18	52.9	8	28.6	26
60–<70	6	17.6	8	28.6	14
70–<80	2	5.9	10	35.7	12
80 and older	0	0.0	2	7.1	2
Total	34	100	28	100	62

In the studied patients, lung ultrasound was diagnostic in 46 cases (74.2%) but failed in 16 cases (25.8%).

Table 2 Outcome of chest ultrasound in the studied patients.

Outcome of LUS	No.	%
Failed	16	25.8
Diagnostic	46	74.2
Total	62	100.0

Table 3 Relation between lung ultrasound and the diagnosis of pneumonia.

Lung ultrasound	Diagnosis of pneumonia		
	Failed No (%)	Diagnostic No (%)	Total
Total	16 (25.8%)	46 (74.2%)	62 (100%)
χ^2	25.99		
<i>P</i> value	0.01		

Chi-Square Test was used, *P* value highly significant ($P < 0.05$).

oes and septations [3,10]. Pleural effusion is classically echo-free. Inflammatory effusion may appear anechoic, complex but non-septated, complex and septated or echogenic [9]. Lung sliding may be absent as a result of adhesions which are seen as mobile strands of echogenic tissue representing fibrin strands [9,15].

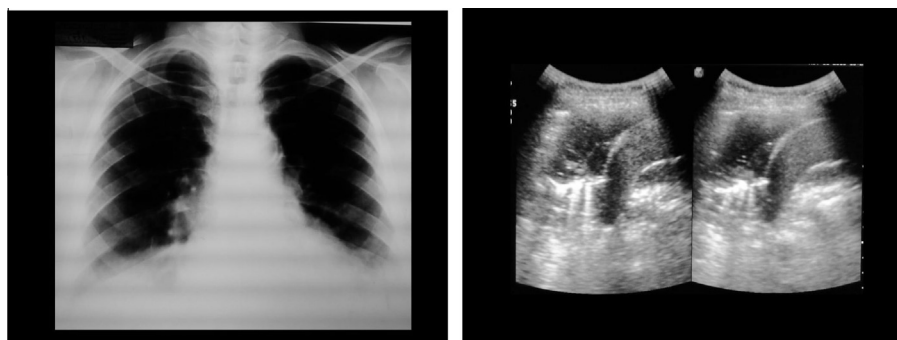


Figure 2 (a) Chest X-ray showed Lt basal ill defined hazy shadow associated with obliterated Lt costophrenic angle. (b) Longitudinal US image revealed Lt basal lung consolidation showing air bronchogram and is associated with mild turbid and partially septated pleural effusion.

Statistical analysis

Statistical package for social science (SPSS, version 10) computer software was used for data entry and analysis.

T-Test, Chi-Square and Fisher's Exact Test were used for comparison between the results.

Mann–Whitney test was used for correlation between results.

P value was calculated and considered significant if < 0.05 .

Results

The study included 62 patients. Their ages ranged from 25 to 80 years with a mean age of 57.74 years, of them 28 were males (45.2%) and 34 were females (54.8%). Most of them were in the age range of 50–60 years (Fig. 1 and Tables 1–3).

There was highly significant relation between the lung ultrasound and the diagnosis of pneumonia.

Sonomorphology of CAP at baseline and during follow-up

Of patients with sonographically detected pneumonia, twenty patients (43%) showed consolidations most frequently on the right side of the lung and in 6 patients on both sides (13%). The consolidation was homogenous in 54%, nonhomogenous in 46% with blurred margins. Median depth was 3 cm. Air bronchogram was detected in 87% of patients and only 13% showed fluid bronchogram. Basal pleural effusion was evident in 54% of patients. (Figs. 2–5 and Table 4).

Discussion

The use of lung ultrasound in the evaluation of pneumonia is growing rapidly and in each clinical setting shows increased efficiency. Although many traditional imaging applications are still indicated and will be used indefinitely for patients with possible pneumonia, lung ultrasound can substantially decrease the practical delays associated with plain chest radiography and in some cases can obviate the need for chest CT when a definitive diagnosis is obtained on ultrasound imaging, avoiding a large radiation dose. In many cases when pneumonia is in the differential diagnosis, lung ultrasound should come first [1].

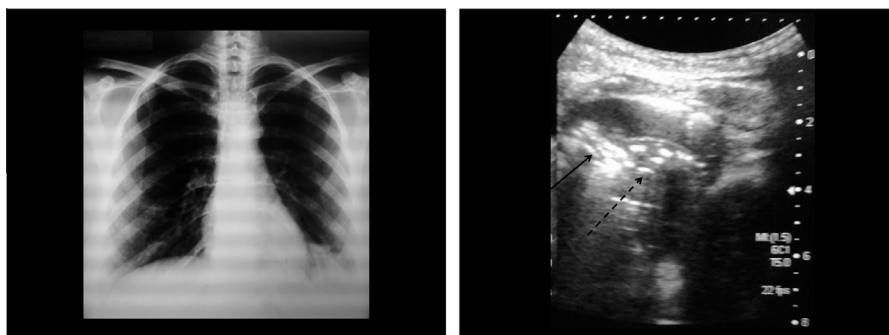


Figure 3 (a) Chest X-ray showed Lt basal paracardiac homogenous shadow associated with obliterated Lt costophrenic angle. (b) Longitudinal US image showed Lt basal lung consolidation containing both air bronchogram (solid arrow) and fluid bronchogram (dashed arrow) associated with minimal pleural effusion.

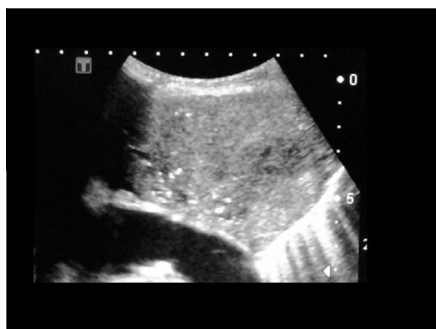

Figure 4 Longitudinal US image showed non homogenous consolidation containing fluid bronchogram associated with pleural effusion.

Combining typical auscultation and positive chest US findings was diagnostic and strong evidence to rule out the disease. Our figures refer to patients with clear US findings. Patients with equivocal results need to undergo further diagnostic procedures [14].

In our study, about 25% of patients, CAP was not detected by chest US because ultrasound can only detect lesions reaching the pleura. In the present study, CAP was confirmed in about 75% of patients as in the study by Parlamento et al, who diagnosed CAP by chest US in about 75% of patients [14].

Table 4 The relation between the X-ray chest and diagnosis of pneumonia.

X-ray chest	Pneumonia		Total
	Failed No (%)	Successful No (%)	
Total	30 (48.4%)	32 (51.6%)	62 (100%)
X^2	4.68		
P value	0.09		

Chi-Square Test was used, P value insignificant ($P > 0.05$).

There is insignificant relation between the X-ray chest and diagnosis of pneumonia.

Air bronchogram was seen in 87%, blurred margins and pleural effusion in 54%. In other studies, air bronchogram was detected in about 70% to 97%, and a pleural effusion was reported in 34% to 61% [16].

Lung ultrasound imaging for the detection of pneumonia is highly accurate but like most diagnostic tests is not perfect. Although pneumonia is the most common cause of lung consolidation, its appearance is non-specific. It is important for the radiologist to realize that infarction, lymphoma, and bronchoalveolar carcinoma can result in consolidation that appears similar to that of pneumonia at US. When the diagnosis is uncertain, US may be used to guide lung biopsy [3,10]. US can easily differentiate between pneumonia and atelectasis [1].

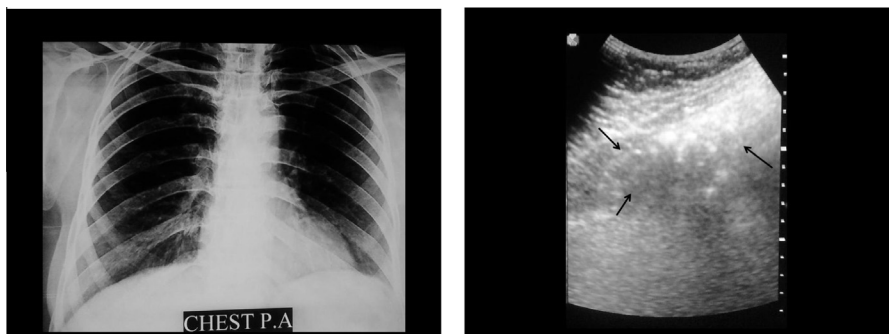


Figure 5 (a) Chest X-ray showed no remarkable findings in patient with suspected pneumonia. (b) Longitudinal US image at upper half of the lateral area of Rt lung showed homogenous area of consolidation containing air bronchogram.

We found that US was able to detect pleural fluid and loculation when compared with chest X-Ray. Chest ultrasound allows resolving the internal components of pleural fluid including fibrin strands, which may indicate early organization of an effusion [10].

Limitations

The present study has several limitations. First, CT chest was not applied in the study for financial reasons and with respect to radiation exposure to cases with positive chest US and negative or equivocal radiographic findings. Second, the study was restricted to patients with suspicion of CAP. Patients who experienced hospital-acquired pneumonia and immunodeficiency were excluded because it is assumed that sonography in these cases may differ. Third, all ultrasounds have been performed by a single experienced radiologist. Although ultrasound diagnosis was established on the basis of objective signs, there are no studies documenting what level of proficiency is necessary for a reliable ultrasound diagnosis of pneumonia. Interobserver agreement among radiologists with different levels of experience and proficiency should thus be investigated further.

Conclusion

Chest ultrasound is a reliable tool for diagnosing pneumonia, probably being superior to chest X-Ray in this setting. It is likely that its wider use will allow a faster diagnosis, rapid therapeutic decisions and follow up. CT scan of the chest is necessary in cases with negative ultrasound results. Although it is unclear as to what level of proficiency is required to perform adequate lung ultrasound, the use of this technique is rapidly expanding. This will probably contribute to a diffuse increase of skills and competence and in the routine use of lung ultrasound in the evaluation of patients with suspected pneumonia.

References

[1] M. Blaivas, Lung ultrasound in evaluation of pneumonia, *J. Ultrasound Med.* 31 (2012) 823–826.

- [2] D.J. Brenner, E.J. Hall, Computed tomography – an increasing source of radiation exposure, *N. Engl. J. Med.* 375 (22) (2007) 2277–2284.
- [3] H.J. Chen, Y.H. Yu, C.Y. Tu, et al, Ultrasound in peripheral pulmonary air-fluid lesions: color Doppler imaging as an aid in differentiating empyema and abscess, *Chest* 135 (2009) 1426–1432.
- [4] Y. Esayag, I. Nikitin, J. Bar-Ziv, et al, Diagnostic value of chest radiographs in bedridden patients suspected of having pneumonia, *Am. J. Med.* 123 (2010) 88.e1e5.
- [5] Francesca Cortellaro, Silvia Colombo, Daniele Coen, Pier Giorgio Duca, Lung ultrasound is an accurate diagnostic tool for the diagnosis of pneumonia in the emergency department, *Emerg. Med. J.* 29 (2012) 19–23.
- [6] O. Gehmacher, Ultrasound pictures of pneumonia, *Eur J Ultrasound.* 3 (2) (1996) 161–167.
- [7] C.P. Heussel, H.U. Kauczor, A.J. Ullmann, Pneumonia in neutropenic patients, *Eur. Radiol.* 14 (2) (2004) 256–271.
- [8] O.H. Kim, W.S. Kim, M.J. Kim, J.Y. Jung, J.H. Suh, US in the diagnosis of pediatric chest diseases, *Radiographics* 20 (2000) 653–671.
- [9] D.M. Koh, S. Burke, N. Davies, S.P.G. Padley, Transthoracic US of the chest: clinical uses and applications, *Radiographics* 22 (2002) e1.
- [10] J. Kurian, T.L. Levi, B.K. Han, B.H. Taragin, S. Weinstein, Comparison of ultrasound and CT in the evaluation of pneumonia complicated by parapneumonic effusion in children, *AJR* 193 (2009) 1648–1654.
- [11] D.A. Lichtenstein, G.A. Mezière, J. Seitz, The dynamic air bronchogram. A lung ultrasound sign of alveolar consolidation ruling out atelectasis, *Chest* 135 (2009) 1421e5.
- [12] D.A. Lichtenstein, G.A. Mezière, Relevance of lung ultrasound in the diagnosis of acute respiratory failure: the BLUE protocol, *Chest* 134 (2008) 117–125.
- [13] C.L. Moore, J.A. Copel, Point of care ultrasonography, *N. Engl. J. Med.* 364 (8) (2011) 749–757.
- [14] S. Parlamento, R. Copetti, S. Di Bartolomeo, Evaluation of lung ultrasound for the diagnosis of pneumonia in the ED, *Am. J. Emerg. Med.* 27 (4) (2009) 379–384.
- [15] J. Reuss, Sonographic imaging of the pleura: nearly 30 years experience, *Eur. J. Ultrasound.* 3 (1996) 125–139.
- [16] M. Sperandio, V. Carnevale, S. Muscarella, et al, Clinical application of transthoracic ultrasonography in patients with pneumonia, *Eur. J. Clin. Invest.* 41 (1) (2011) 1–7.
- [17] H. Syrjala, M. Broas, I. Suramo, et al, High-resolution computed tomography for the diagnosis of community-acquired pneumonia, *Clin. Infect. Dis.* 27 (1998) 358e63.